



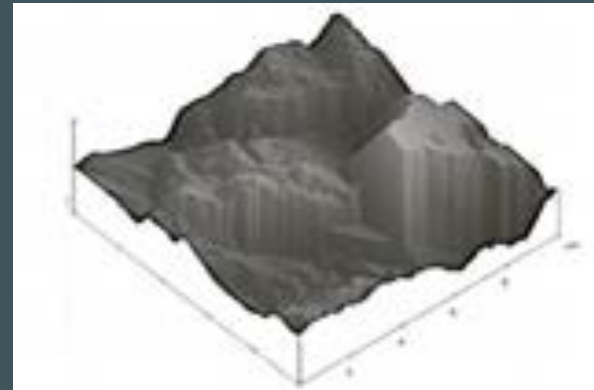

Superior Implant Technology



New A.B. Dental Implant I22

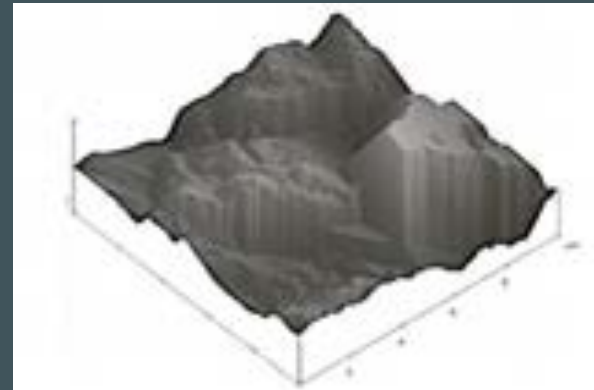

**Gustavo F. Yatzkaier DDS
Oral & Maxillofacial Surgeon**

AB Implants:
Surface:
Biological blasting with $\text{Ca}_3(\text{PO}_4)_2$ for surface
roughening.



The wide particle range bioactive ceramic media blasting with mild gradative multi-step cleaning assures a moderately rough surface along with a highly biocompatible surface chemistry where only osseo-conductive and biocompatible elements can be detected.

Albrektsson T, Wennerberg A. Oral implant surfaces: Part 1 –review focusing on topographic and chemical properties of different surfaces and in vivo responses to them: *Int J Prosthodont* 2004;17(5):536-43.





Double platform-deep (hex connection) and flat (non hex connection)

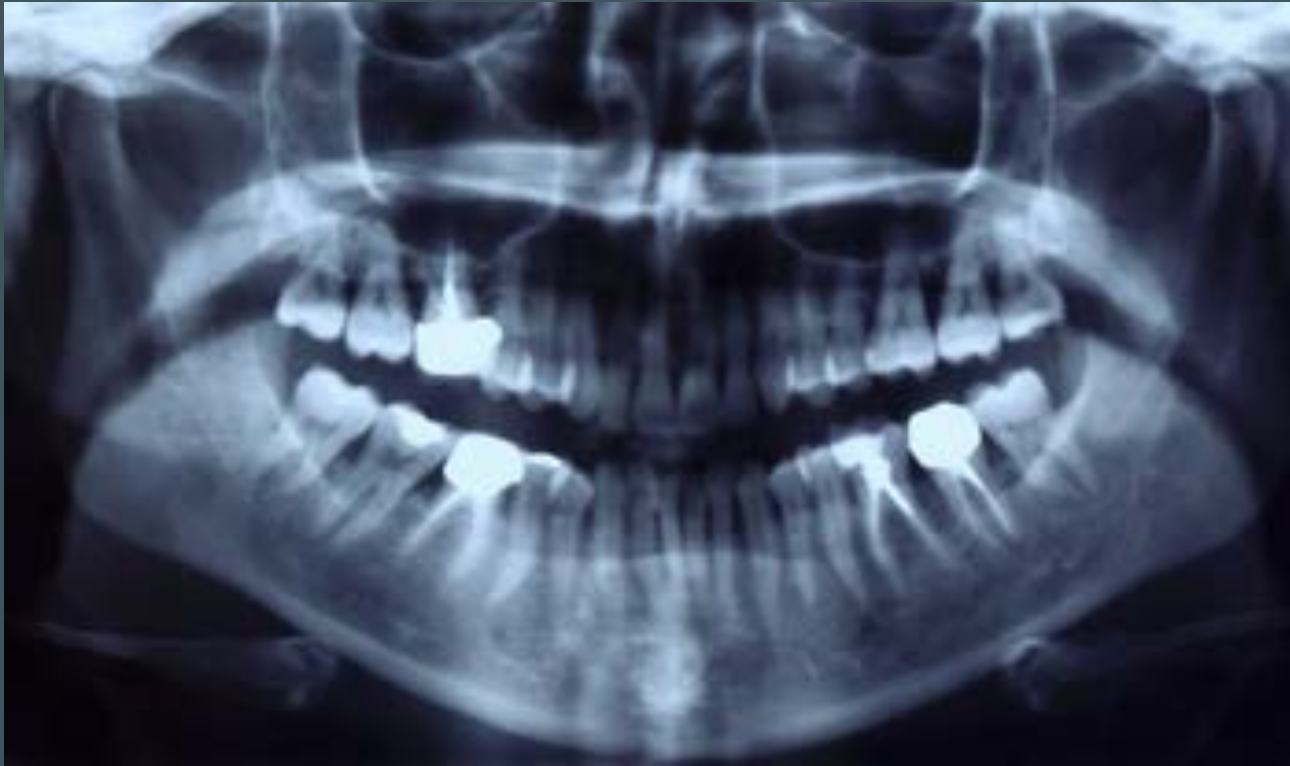Equipped with switch platform

Gentle, double and dense threads

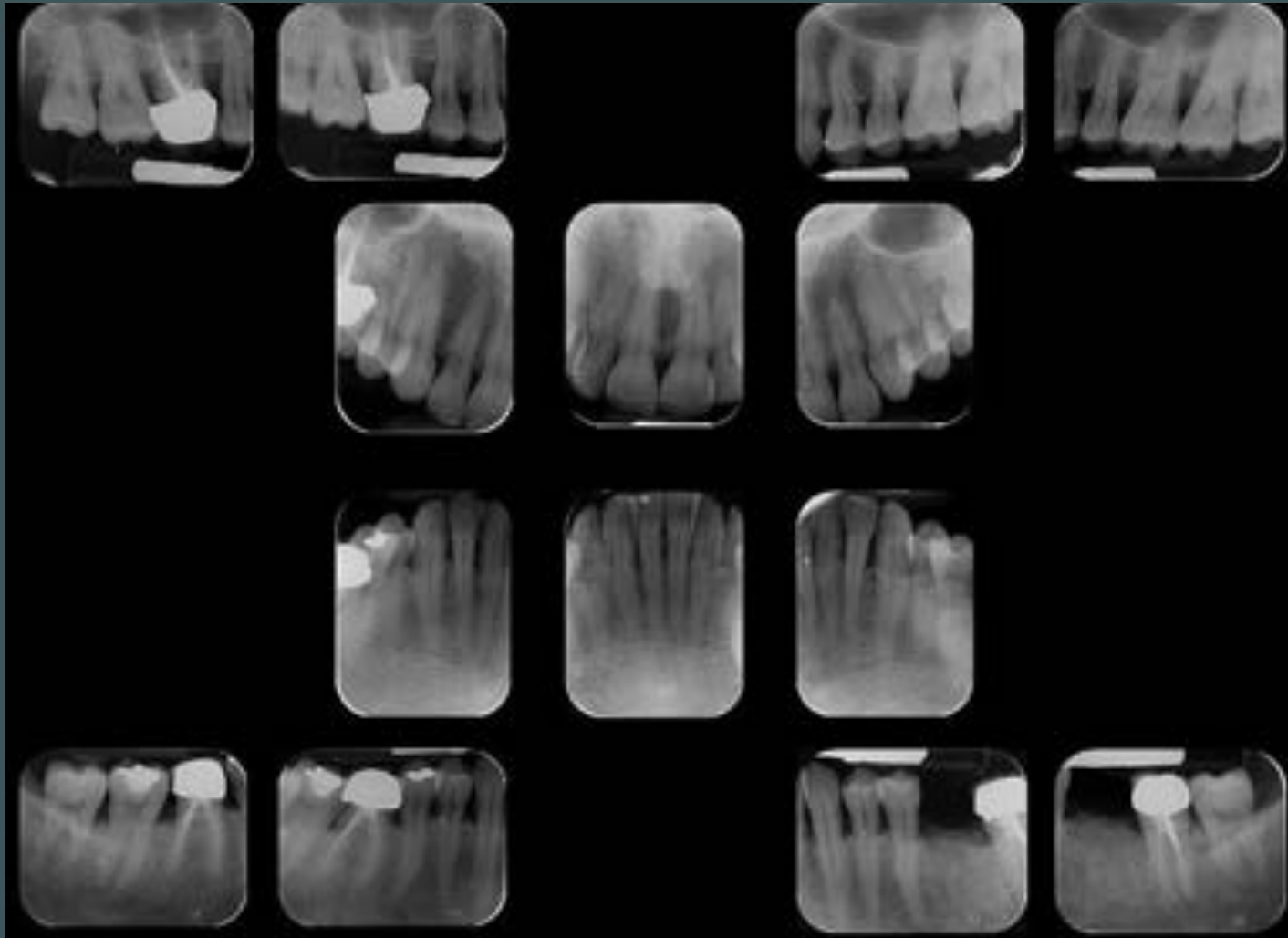


Dense bone type
Immediate implantation
Immediate loading

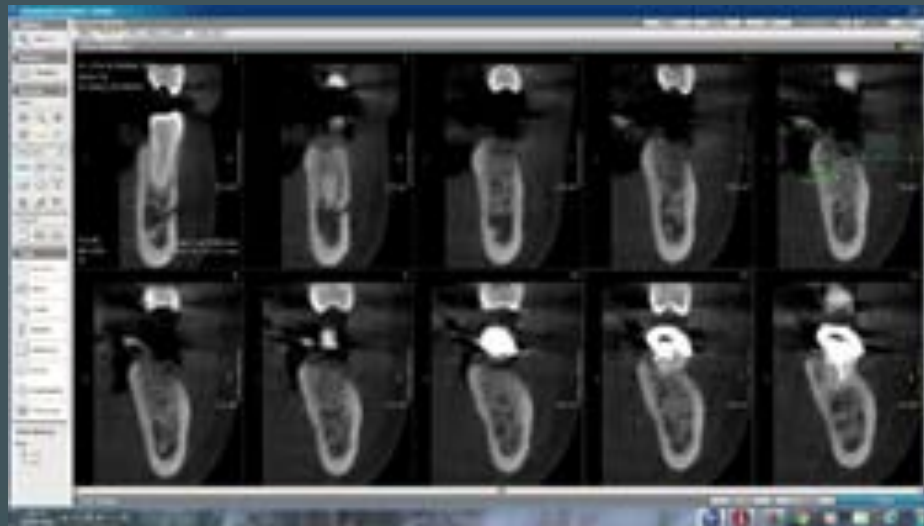
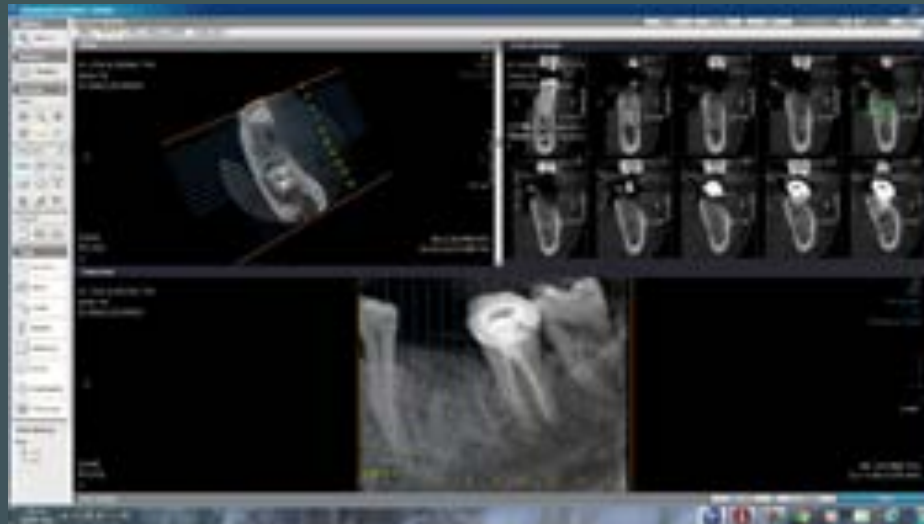- 50 year-old woman
- Healthy
- # 36 extraction
- # 36 delayed implantation
- I22 4-2/10mm implant

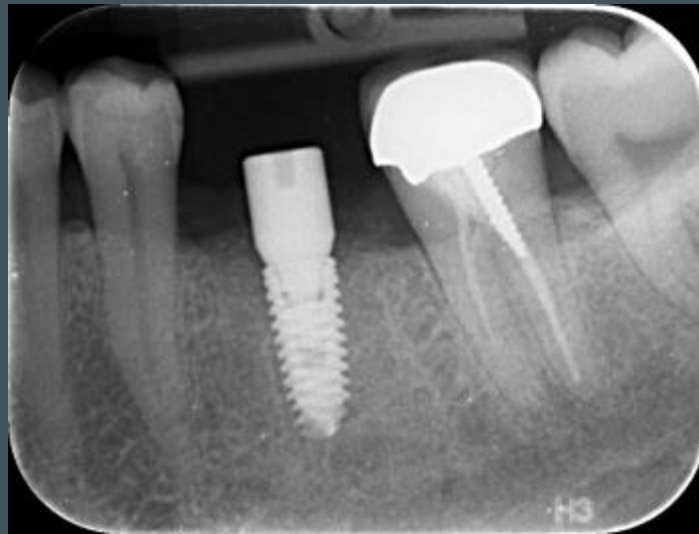

I22 CASE 1

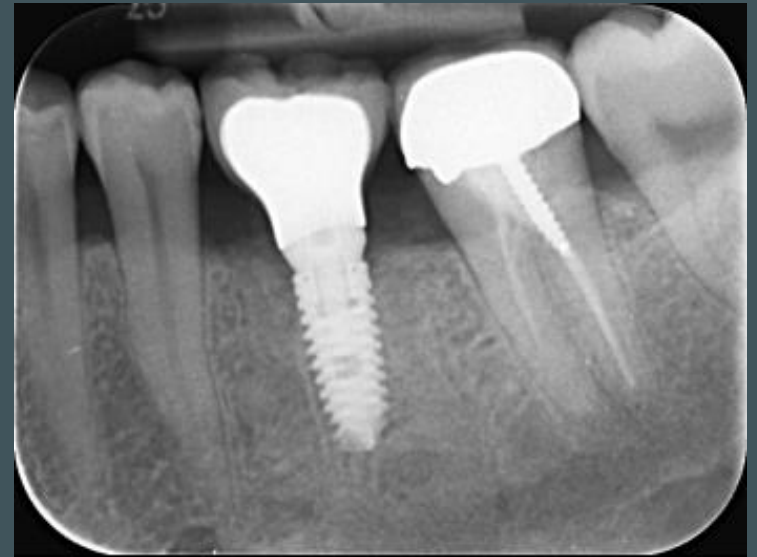
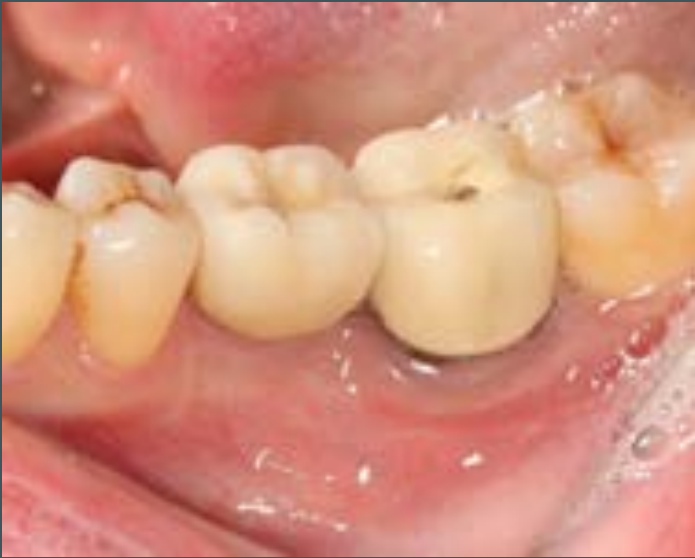
I22 CASE 1

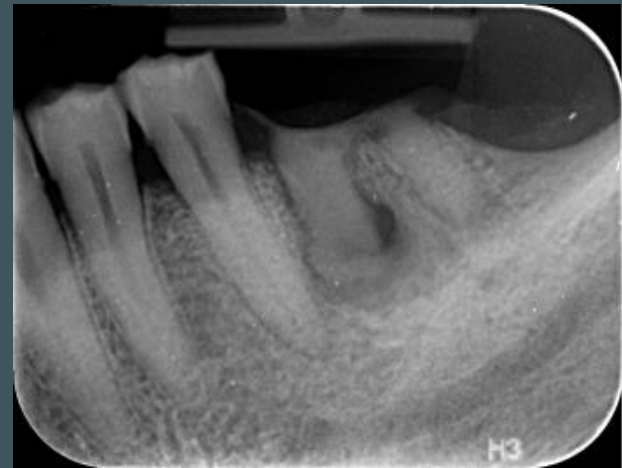
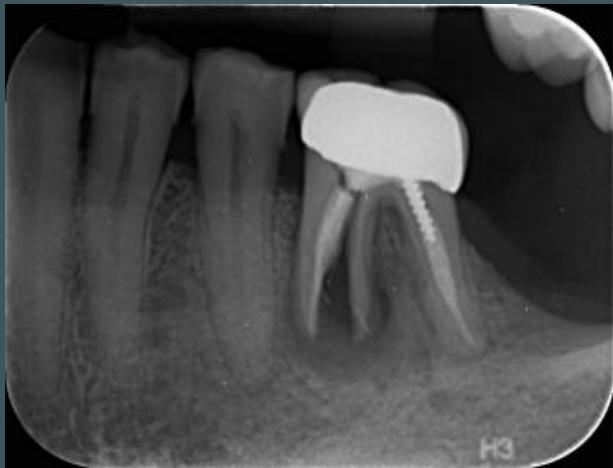

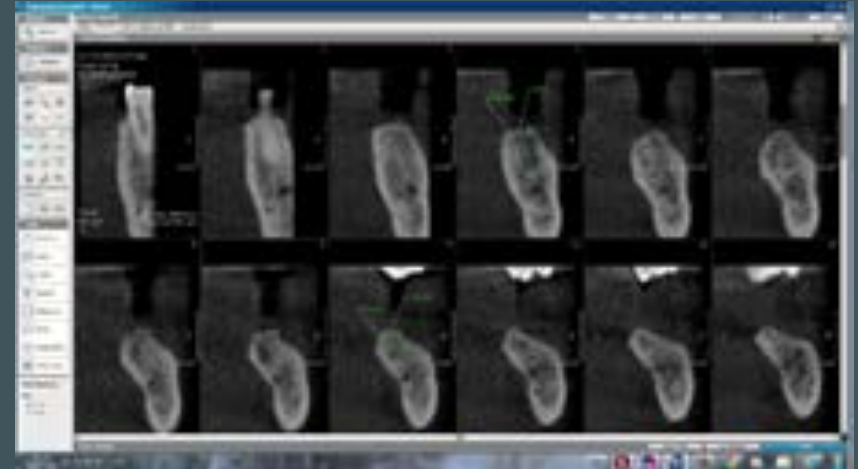

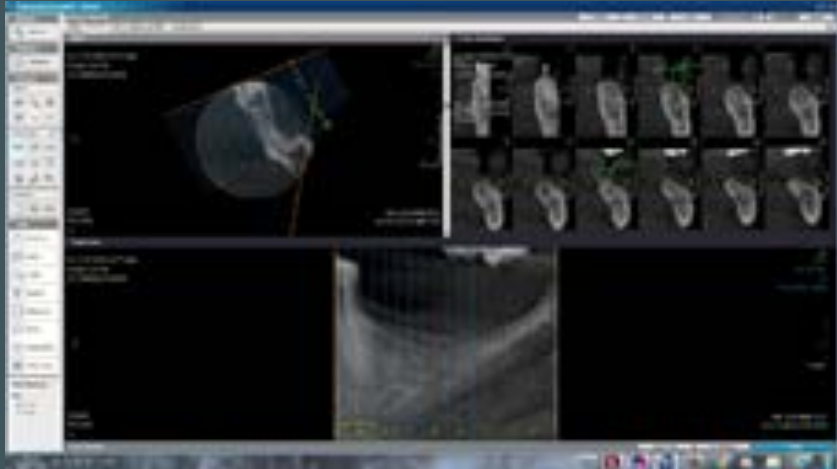




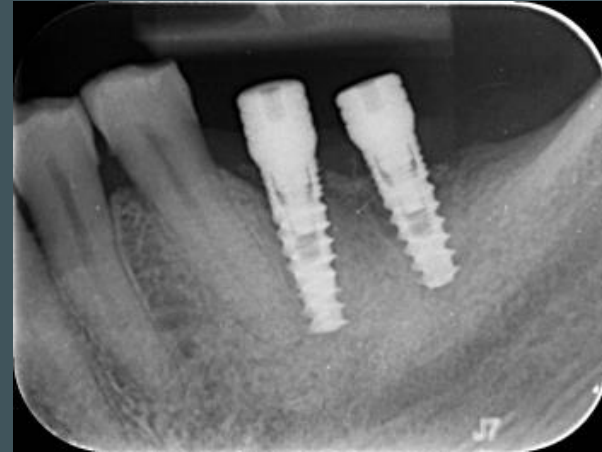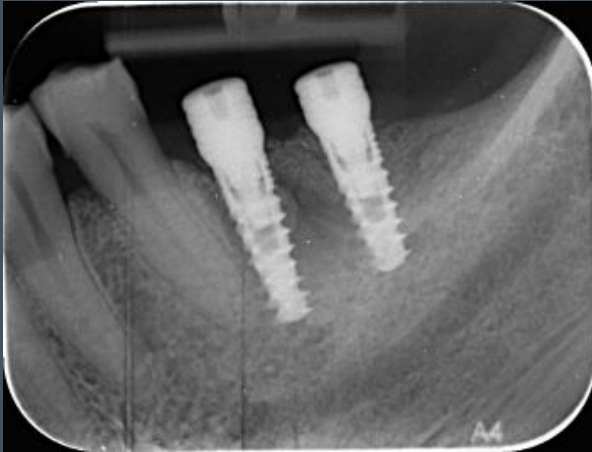- 55 year-old man
- Healthy
- # 36 extraction
- # 36 two implants with deep threads failed
- Two I22 3-75/10mm implants inserted

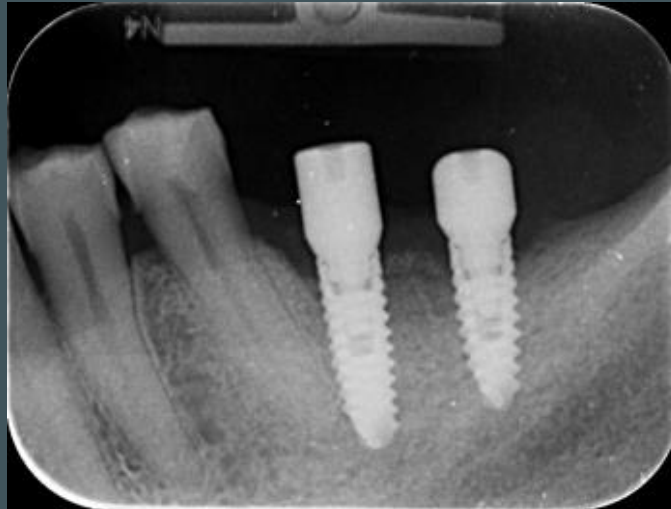




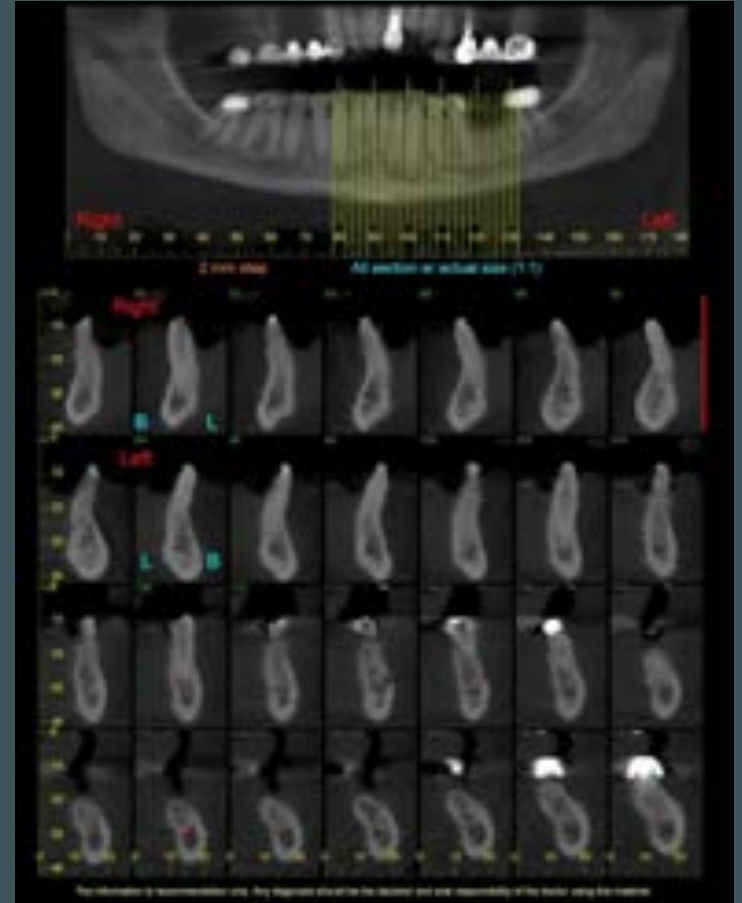
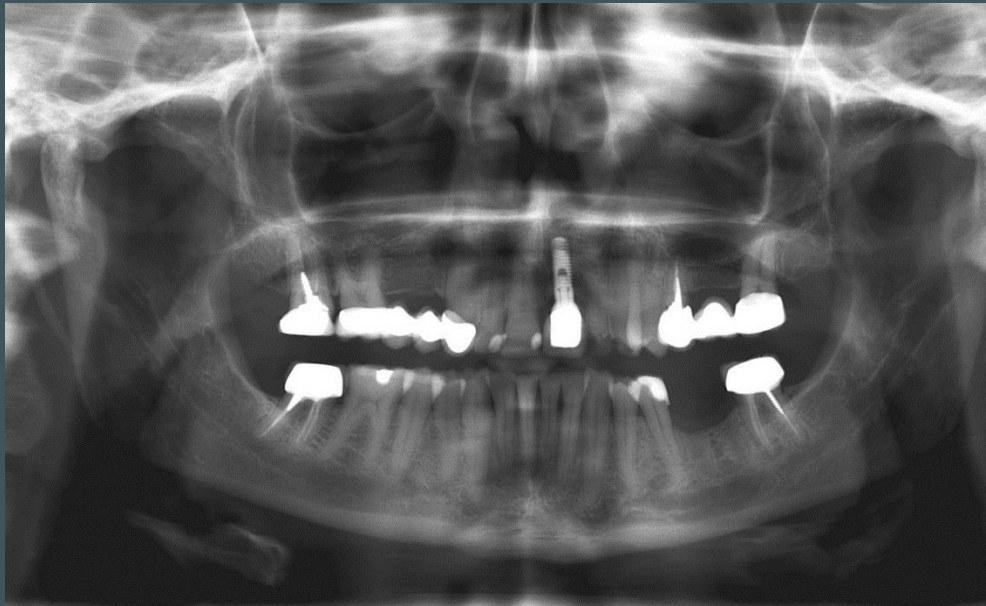
Two wide threads implants failed



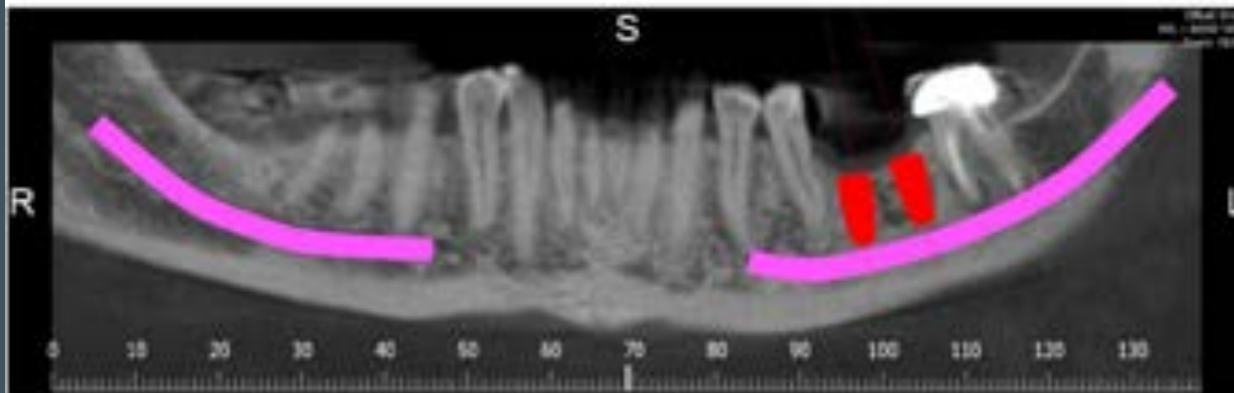
Two I22 implants inserted







- 54 year old woman
- Healthy
- Two implants in #36 area
- Mesial implant failed replaced by I22
- Tooth supported guide

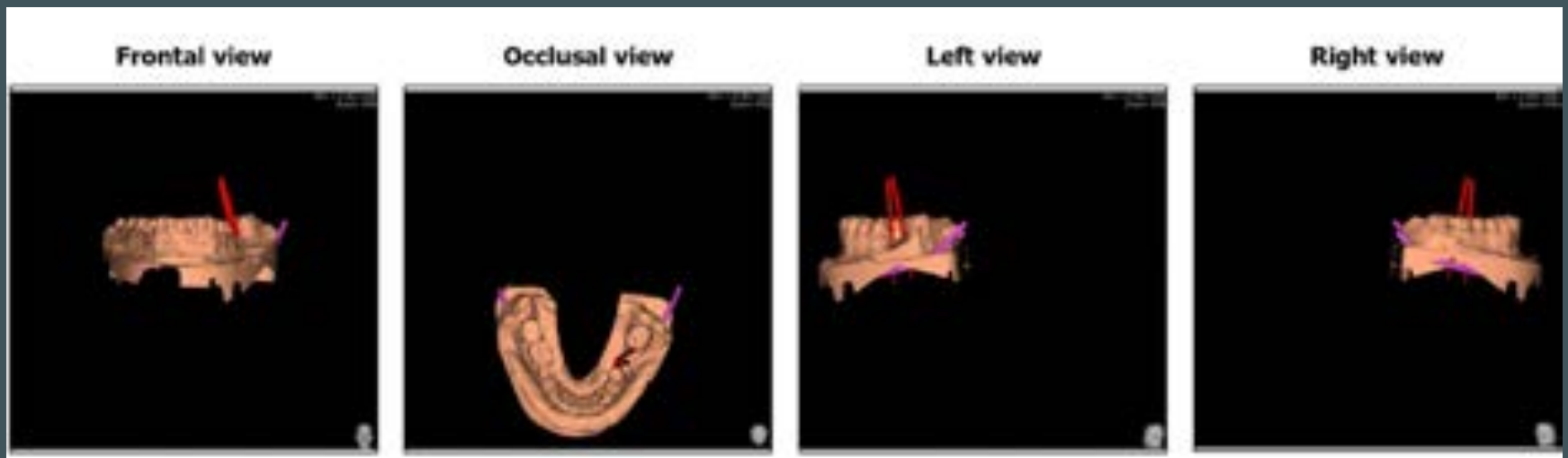


PLANNING OVERVIEW

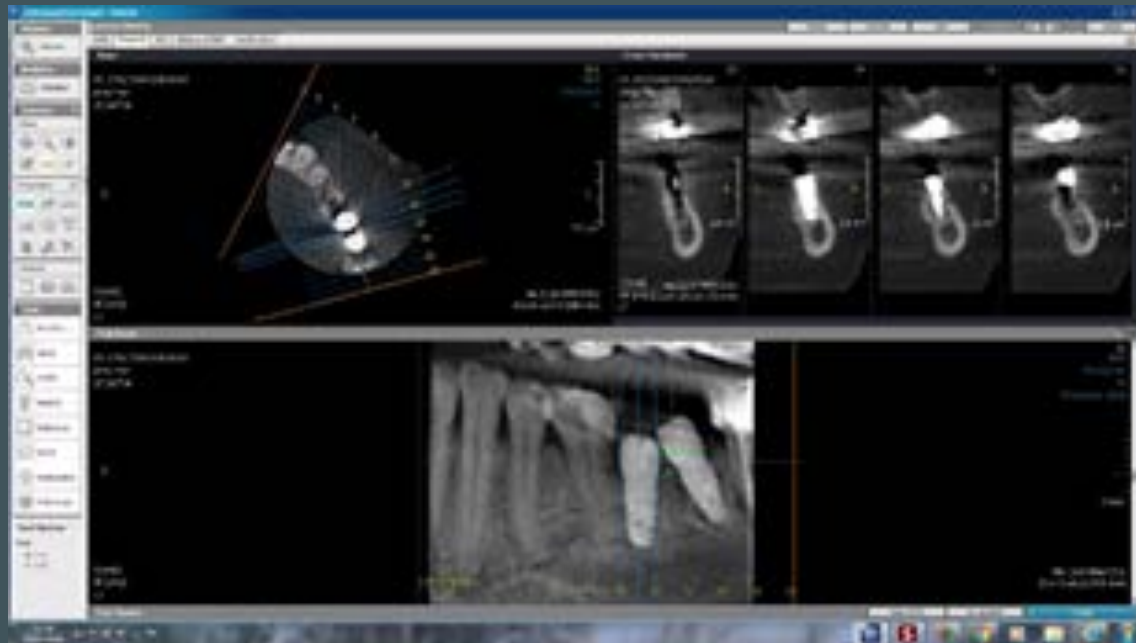

Notes:
 PLAN 2
 ON LINE PLANNING

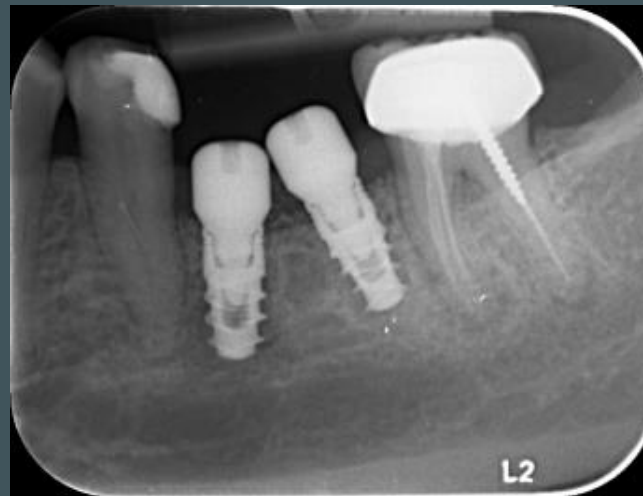Implant	Manufacturer	Model	Size	Drill	Mount	Healing cap	Abutment
35	AB Dent	IS Conical Implant	3.75 x 8.0 mm				
36	AB Dent	IS Conical Implant	3.75 x 8.0 mm				



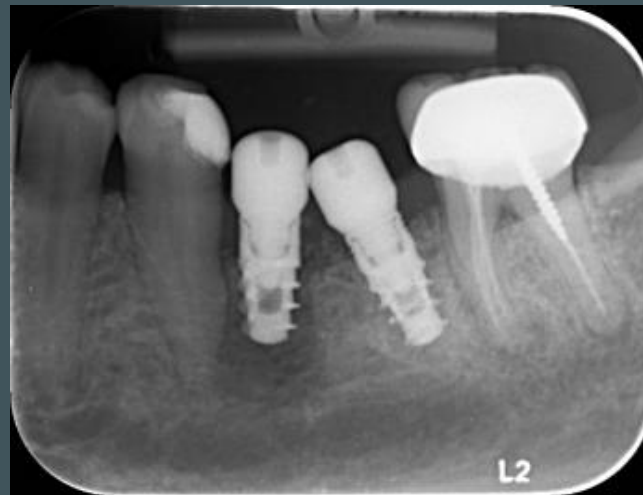04-07-2016 implantation



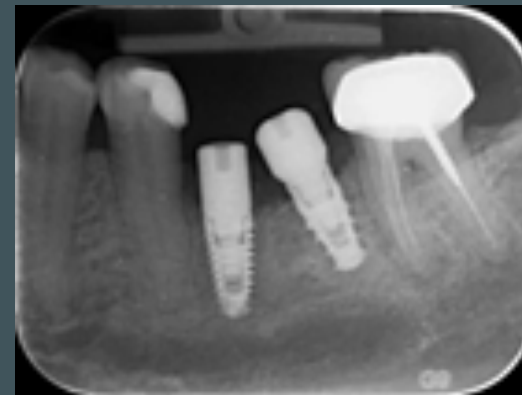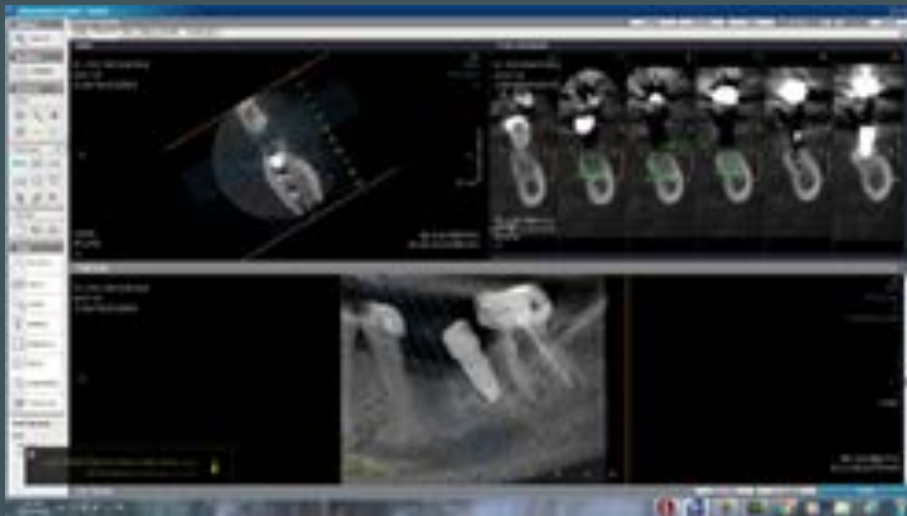20-07-2016 swelling, unclear pain



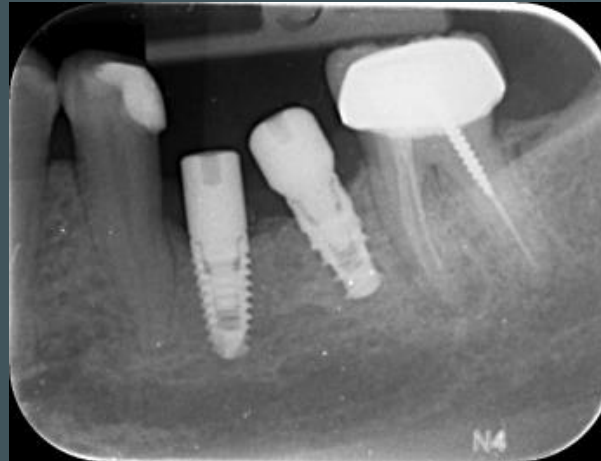
27-07-2016 implant removal



27-10-2016 new implantation

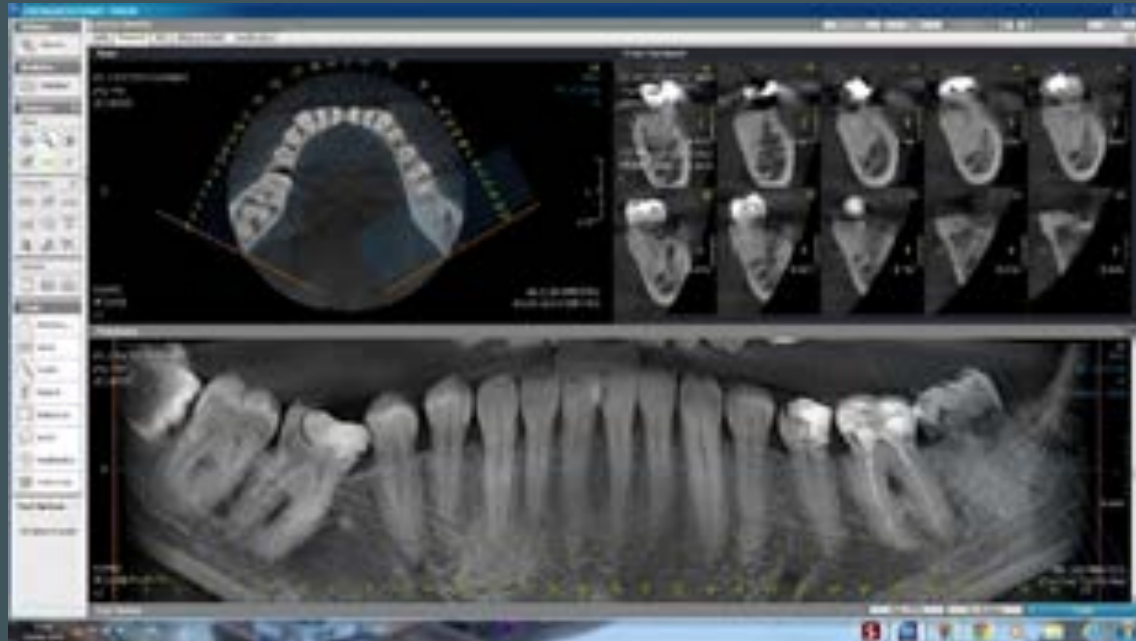

16-02-2017 approval of rehabilitation

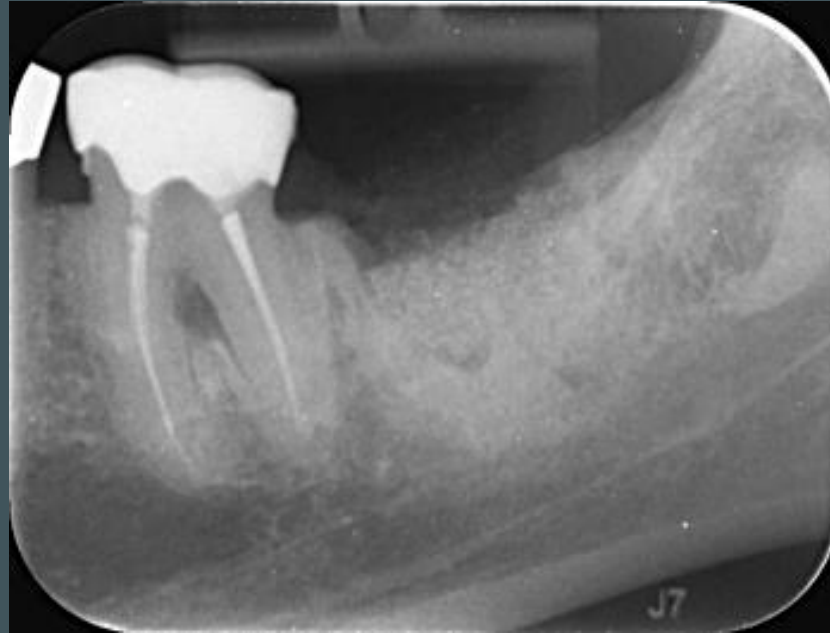

- 56 year old man
- Healthy
- Hypercementosis in 37 area
- #37 extracted
- Delayed I22 implantation
- Type 1 bone

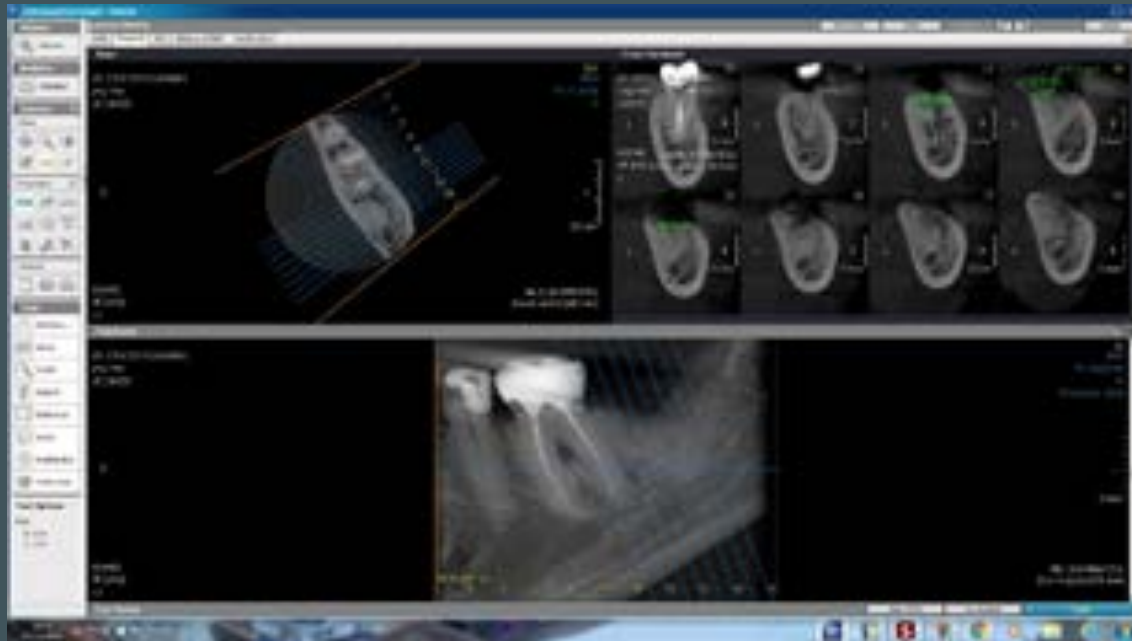
#37 need to be extracted



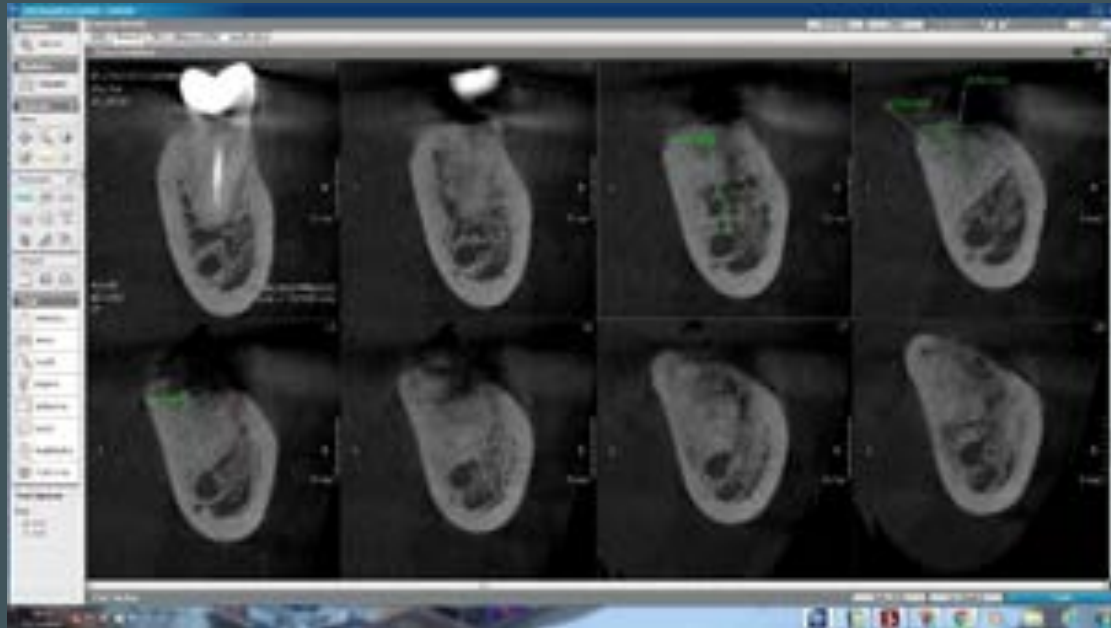
**Very difficult extraction, may be root remnants
were left in socket**



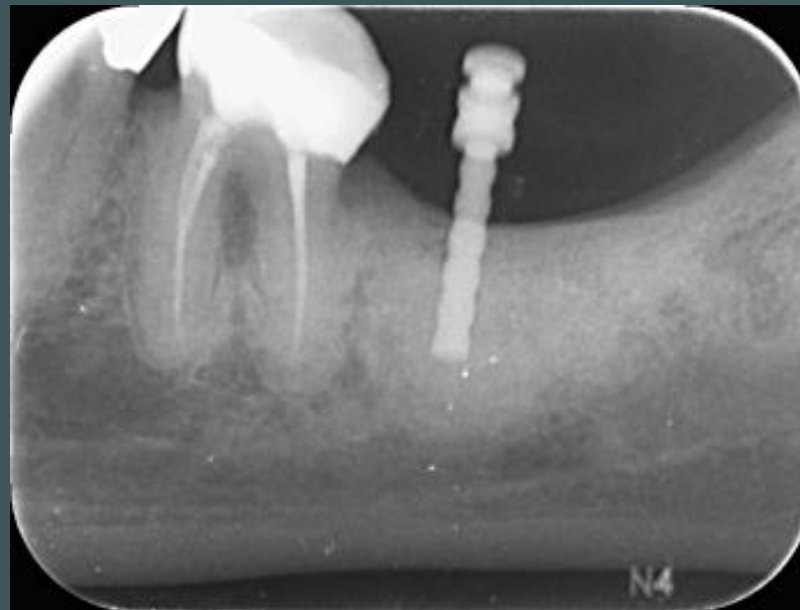
Pre-operative Cbct was done



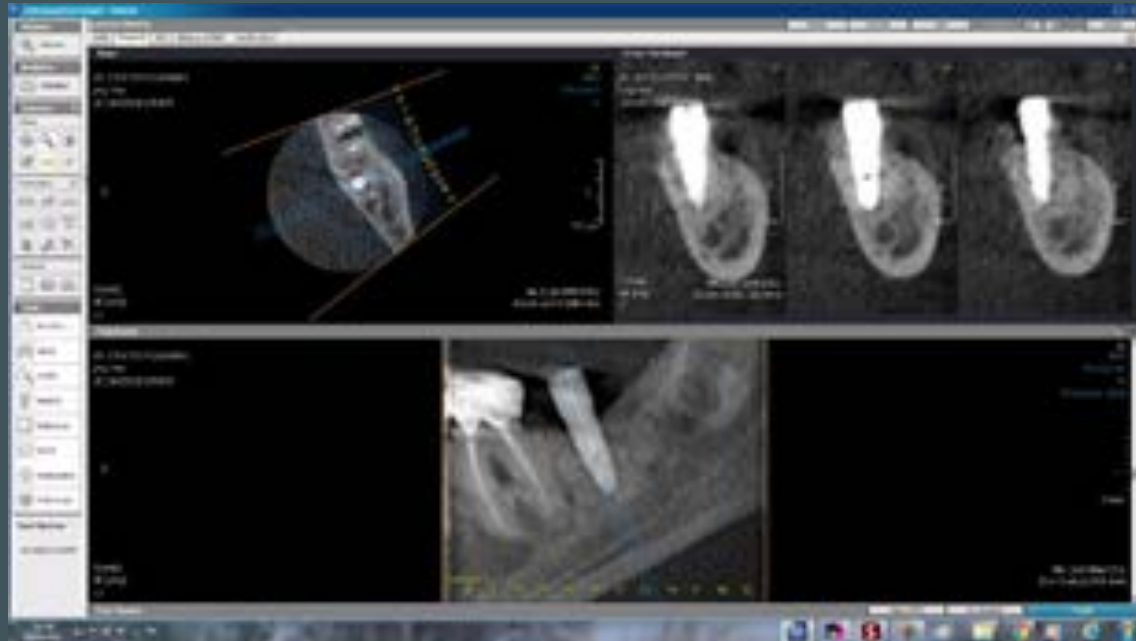
Pre-operative Cbct was done



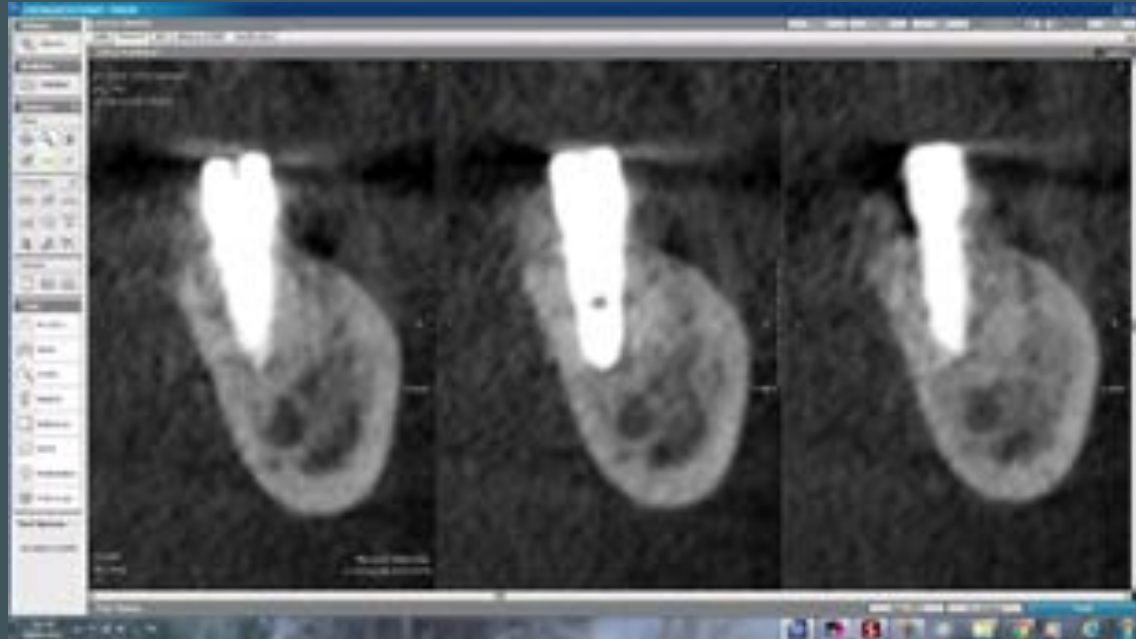
Intra-operative Rx



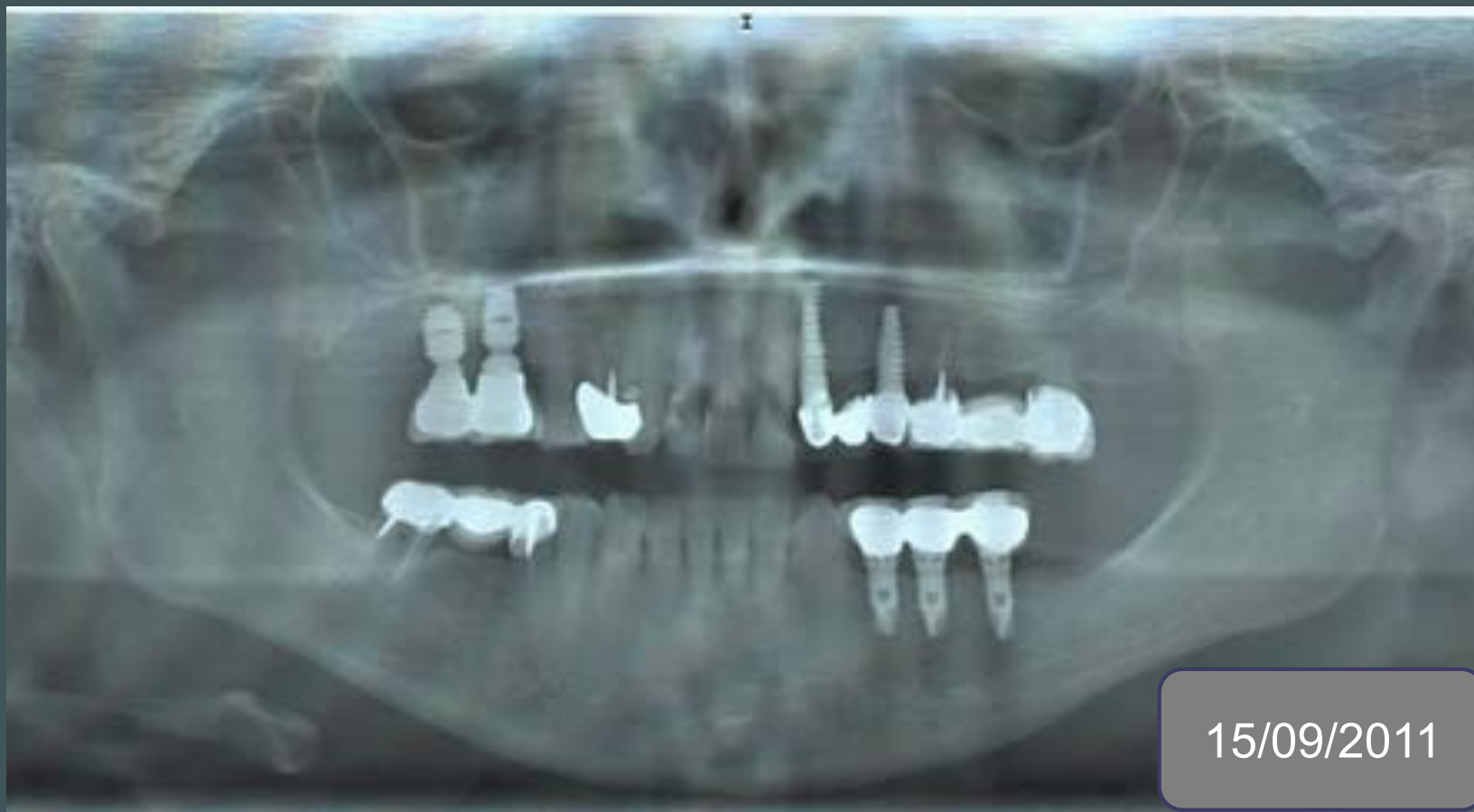Intra-operative Rx



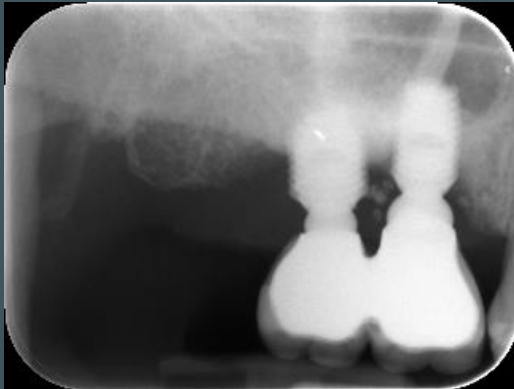
Intra-operative Rx



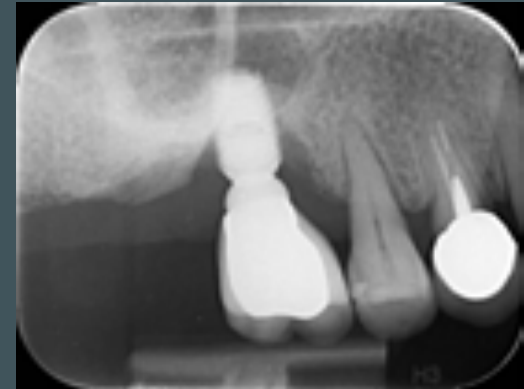- 62 year old woman
- Healthy
- Failed previous implants #16-#17
- #15 extraction tooth, #16-#17 implants removal
- Delayed # 15 I22, # 16 I10, #17 I55 implantation
- Crestal hydraulic sinus augmentation #16

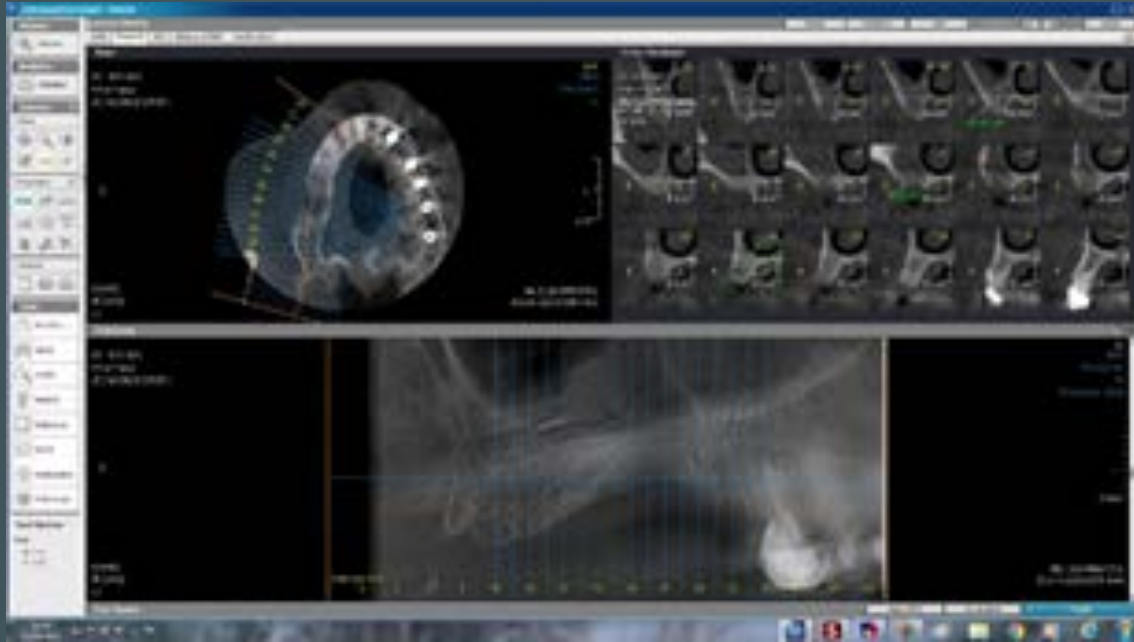


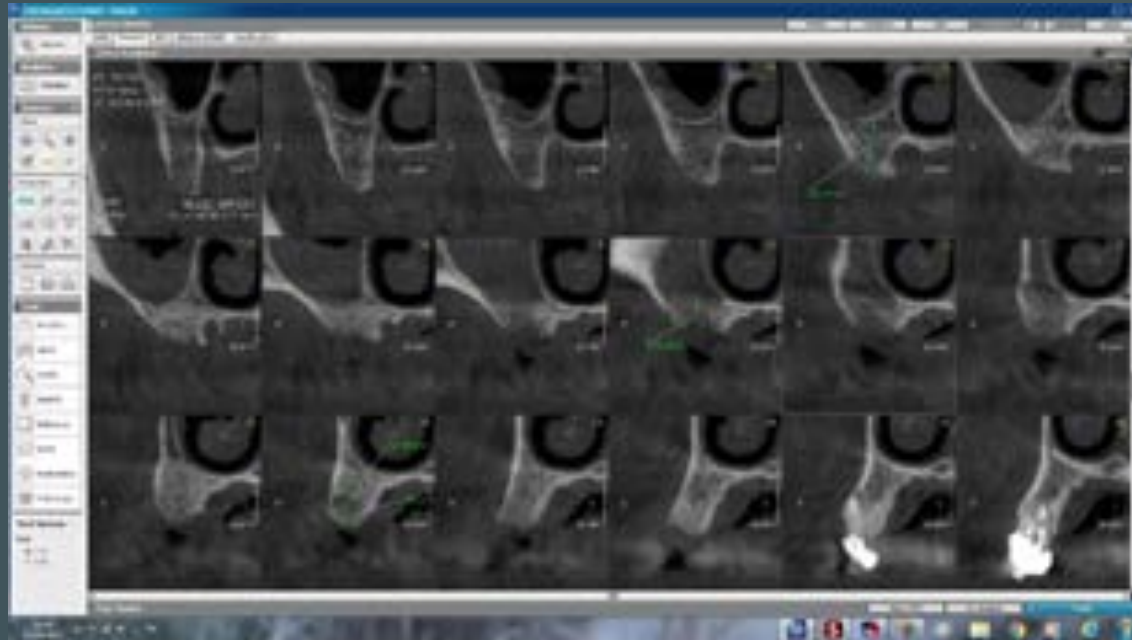
13/11/2012

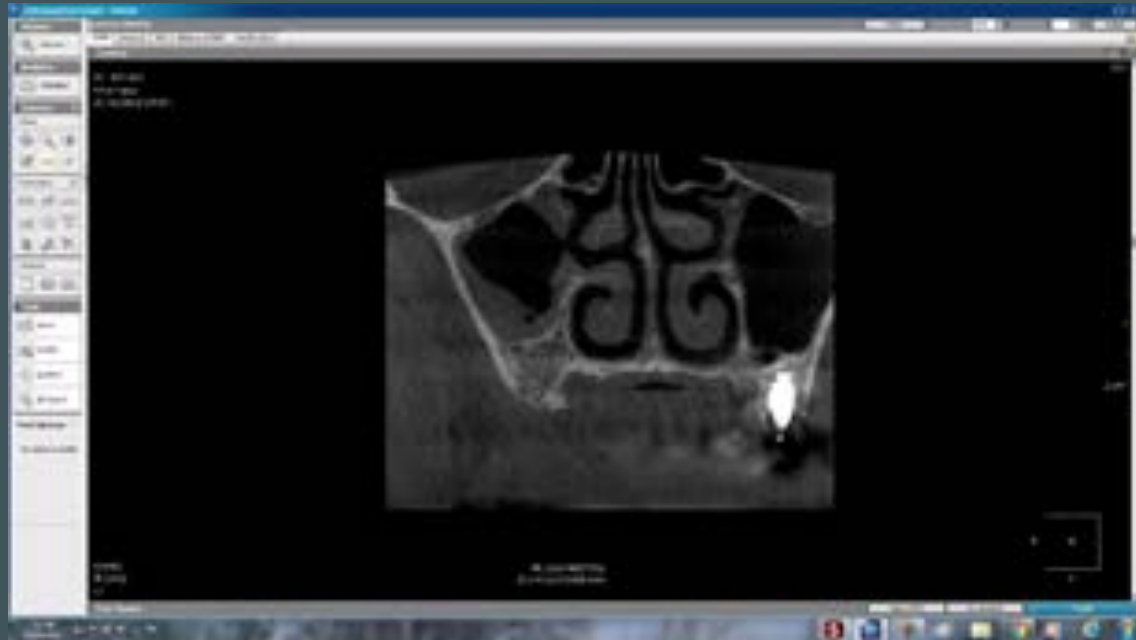


18/12/2015

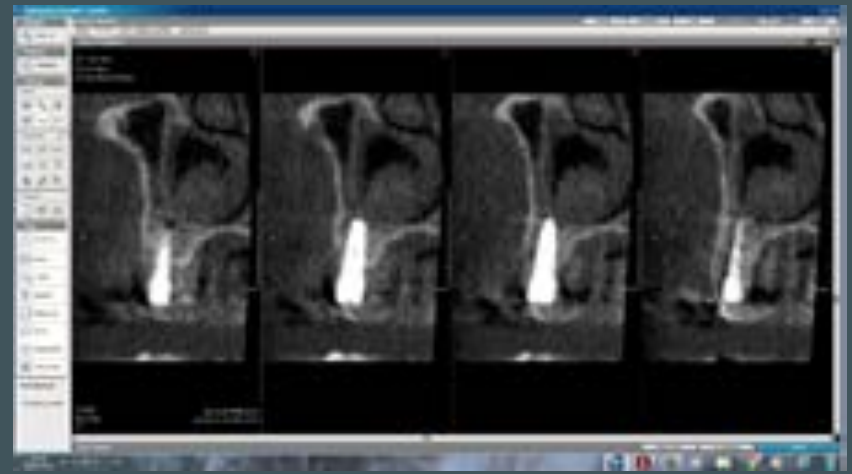
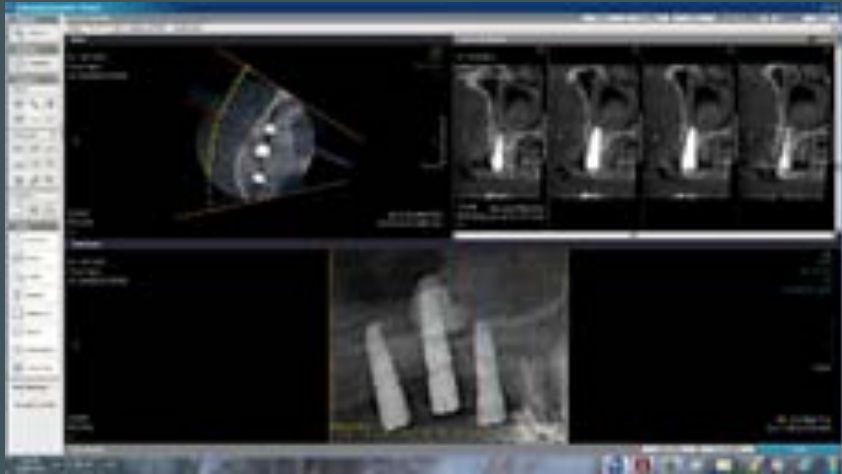




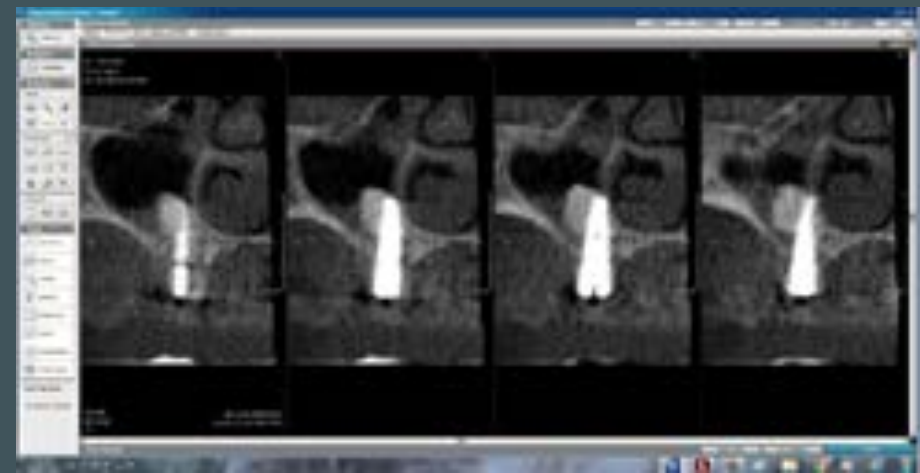
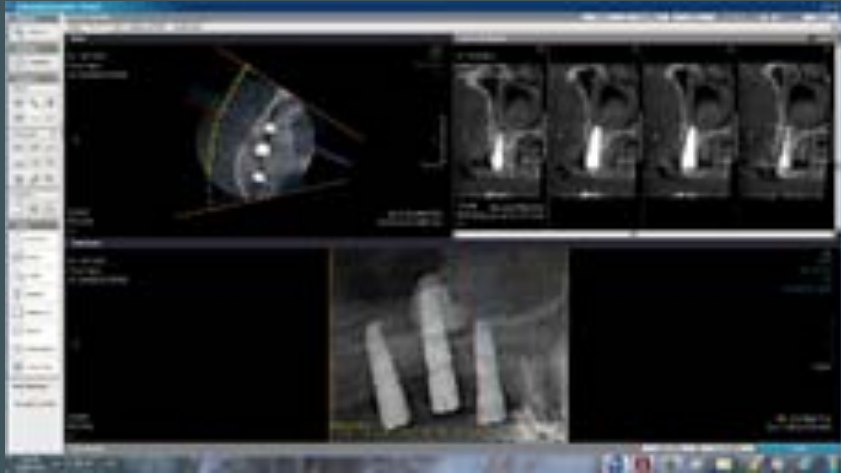
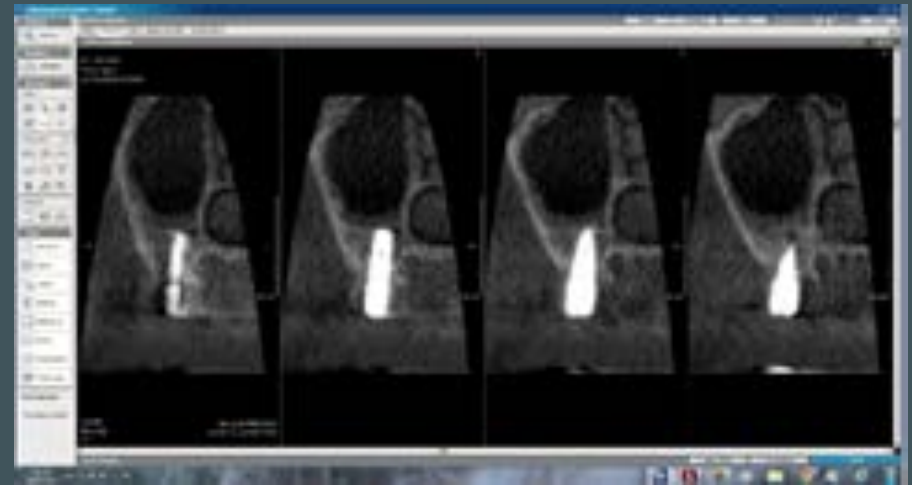I-22 #15



I-10 #16 Crestal hydraulic sinus augmentation



I-55 #17



Thank you for your kind attention!!!

